



Research Article

Linked Color Imaging and Color Analytic Model Based on Pixel Brightness for Diagnosing *H. Pylori* Infection in Gastric Antrum

 Xiaotian Sun,^{1,2}  Cuiyun Ma,²  Xueting Zhang,²  Chang Lu,³  Haiyan Yu,²  Wei Zhang,¹  Ying Wang,³
 Shaoying Zhu,³  Minglu Liu,¹  Huiming Zhang,³  Xinfang Miao,³  Yang Xu²

¹Department of Internal Medicine, Southern Medical Branch of PLA General Hospital, Beijing, China

²Department of Gastroenterology, the Fifth Medical Center of PLA General Hospital (the 307 Hospital of Academy of Military Medical Science), Beijing, China

³Clinic of Fuxing Road, Southern Medical Branch of PLA General Hospital, Beijing, China

Abstract

Objectives: Linked color imaging (LCI) helps to differentiate minor mucosal changes, which can be objectively judged by red–green–blue pixel brightness. However, whether this color analytic model based on pixel brightness can be applied to diagnose *Helicobacter pylori* infection remains unknown.

Methods: Consecutive adult patients with indications and underwent esophagogastroduodenoscopy for the 1st time were enrolled in the training (n=166) and validation (n=79) set. Demographic and clinical characteristics were recorded. Target region in gastric antrum was pictured before biopsy for rapid urea test, and pixel brightness was calculated by MATLAB software.

Results: In training set, 25 patients had *H. pylori* infection. Pixel brightness for R and B in patients with *H. pylori* infection was greatly higher than those in patients without *H. pylori* infection (R: 210.203±27.233 vs. 196.401±29.018, p=0.043; B: 127.621±26.112 vs. 125.334±27.812, p=0.025). At the cut off of R = 210 and B = 127, the specificity and sensitivity were 0.696 and 0.701. In validation set, 10 patients had *H. pylori* infection and the findings were consistent with those in training set.

Conclusion: Color analytic model based on pixel brightness under LCI was useful in diagnosing *H. pylori* infection in gastric antrum.

Keywords: Diagnostic efficacy, Esophagogastroduodenoscopy, *H. pylori* infection, Linked color imaging, Pixel brightness value

Cite This Article: Sun X, Ma C, Zhang X, Lu C, Yu H, Zhang W, et al. Linked Color Imaging and Color Analytic Model Based on Pixel Brightness for Diagnosing *H. Pylori* Infection in Gastric Antrum. EJMO 2023;7(2):160–164.

The incidence of gastrointestinal diseases has been on the increase both at home and abroad in the recent years, and the esophagogastroduodenoscopy has already become the main tool for diagnosing and treating gastrointestinal mucosal lesions.^[1,2] *Helicobacter pylori* infection is one of the most common gastrointestinal disorders. *H. pylori* infection occurs often in the gastric antrum and it has been proved that *H. py-*

lori infection was associated with a series of human diseases and even a variety of malignancies.^[3–5] Some patients with *H. pylori* infection may have non-specific dyspeptic symptoms such as abdominal distension, stomach pain, heartburn, and the like, while more than half of the patients can be asymptomatic, making it easily neglected. The diagnosis of *H. pylori* can be confirmed by pathology and rapid urease test of the

Address for correspondence: Yang Xu; Xinfang Miao, MD. Department of Gastroenterology, the Fifth Medical Center of Chinese PLA General Hospital, No. 8 East Road, Beijing 100071, China; Clinic of Fuxing Road, Southern Medical Branch of PLA General Hospital, Beijing 100161, China
Phone: 86-010-66933216; 86-010-66887393 **E-mail:** 13818223446@163.com; miaoxinfang@hotmail.com

Submitted Date: December 10, 2022 **Revision Date:** February 02, 2023 **Accepted Date:** April 11, 2023 **Available Online Date:** June 19, 2023

©Copyright 2023 by Eurasian Journal of Medicine and Oncology - Available online at www.ejmo.org

OPEN ACCESS This work is licensed under a Creative Commons Attribution-NonCommercial 4.0 International License.



biopsied mucosa in gastric antrum. *H. pylori* in the stomach has close relationships with the development and progression of mucosal atrophy, peptic ulcer, intestinal metaplasia, and gastric cancer.^[6]

Our former research has found that linked color imaging (LCI) could be able to benefit the endoscopic diagnosis of *H. pylori* infection in the stomach.^[7-9] LCI has been recently developed to improve the diagnostic efficacy of gastrointestinal endoscopy. Several previous studies have reported that LCI technique can make the red area redder and white area whiter by light modification and digital post-processing. We have also proposed a color analytic model based on the objective calculations of pixel brightness values for red, green, and blue (RGB) to differentiate the hue characteristics of LCI images.^[9] However, whether pixel brightness value can be used as an objective parameter for making diagnosing has still not been clearly investigated. Thus, in this study, we first enrolled a training set of consecutive patients to establish a threshold of the pixel brightness values for diagnosing *H. pylori* infection in gastric antrum and then further included a validation set to confirm its diagnostic efficacy in routine practice.

Patients and Methods

Patients

A total of 166 consecutive adult patients who had indications and underwent esophagogastroduodenoscopy for the 1st time were enrolled in the Endoscopy Center of the Fifth Medical Center of Chinese PLA General Hospital from May 1, 2021, to August 31, 2021 (training set). Another set of 79 consecutive adult patients who had indications and underwent esophagogastroduodenoscopy for the 1st time from September 1, 2021, to October 30, 2021 was included in the validation set. Patients with suspected malignant lesions and previous history of *H. pylori* infection were excluded. The flow chart of the study was shown in Figure 1. All the patients gave their written informed con-

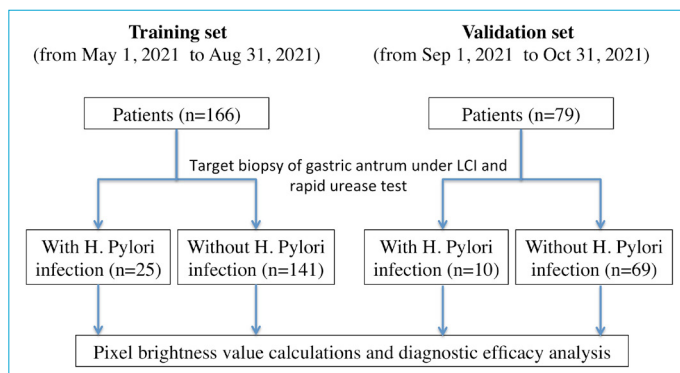


Figure 1. Flow chart of this study.

sent, and our study was approved by the Ethic Committee of the Fifth Medical Center of Chinese PLA General Hospital (the 307 Hospital of Academy of Military Medical Science) in accordance with the Declaration of Helsinki. The demographic and clinical characteristics of all the patients were recorded.

Esophagogastroduodenoscopy and *H. Pylori* Infection

All the esophagogastroduodenoscopic examinations were completed using EC-L590ZW endoscope with the LASEREO system (FUJIFILM Co., Tokyo, Japan) by experienced endoscopists (>1000 esophagogastroduodenoscopic procedures). No intravenous anesthesia was applied. The whole stomach was routinely checked. The target region of the antrum was pictured and then the biopsy was performed (Fig. 2). Rapid urease test of biopsied gastric mucosa was applied to test *H. pylori* infection according to the protocol.

Calculations of Pixel Brightness Value

MATLAB software (Matlab, the USA) was used to calculate the R, G, and B pixel brightness value of the target regions in LCI images.^[8] R, G, and B pixel brightness value of *H. pylori* infection and *H. pylori* non-infection was compared. The diagnostic efficacy of R, G, and B pixel brightness value for *H. pylori* infection was estimated and receiver-operating characteristic (ROC) curve was drawn. Sensitivity, specificity, and area under curve (AUC) were calculated.

Statistical Analysis

All the statistical analysis was performed by SPSS software. Continuous and categorical data were presented as mean±standard deviation and percentage (%), respectively. The student t-test and Chi-square test were used to check the differences. A two-tailed P value less than 0.05 was considered as statistical significance.

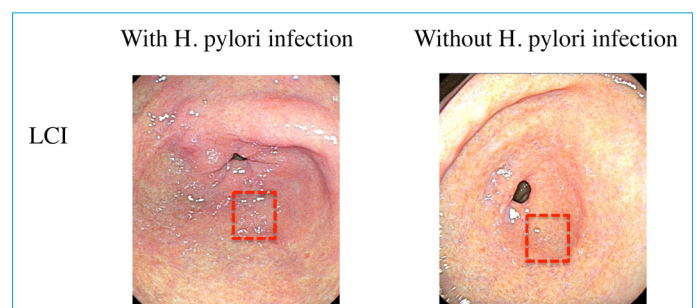


Figure 2. Typical LCI images of gastric antrum and the manual selection of target region for biopsy and pixel brightness value calculations by MATLAB software.

Results

Demographic and Clinical Characteristics of the Training Set

In the training set, 25 patients had *H. pylori* infection. There were no significantly statistical differences on the age, gender, and main symptoms (all $p > 0.05$) (Table 1). *H. pylori* infection was obviously correlated with chronic atrophic gastritis ($p = 0.000$).

Pixel brightness values for R and B in patients with *H. pylori* infection were greatly higher than those in patients without *H. pylori* infection (R: 210.203 ± 27.233 vs. 196.401 ± 29.018 , $p = 0.043$; B: 127.621 ± 26.112 vs. 125.334 ± 27.812 , $p = 0.025$).

Diagnostic Efficacy for H. Pylori Infection

ROC on pixel brightness value of R and B for diagnosing *H. pylori* infection was drawn, respectively. At the cut off of R = 210 and B = 127, the specificity, sensitivity, and AUC were 0.696, 0.701, and 0.748, respectively (Table 2).

Validation

In the validation set, 10 patients had *H. pylori* infection. There were no significantly statistical differences on the age, gender, and main symptoms (all $p > 0.05$) (Table 3). *H. pylori* infection was obviously correlated with chronic atrophic gastritis ($p = 0.002$).

Pixel brightness values for R and B in patients with *H. pylori* infection were greatly higher than those in patients without *H. pylori* infection (R: 212.311 ± 28.004 vs. 197.106 ± 28.182 , $p = 0.031$; B: 128.718 ± 28.202 vs. 124.984 ± 27.832 , $p = 0.044$). Using the criteria of R > 210

Table 2. Diagnostic efficacy analysis in the training set

Cut-off value	R>210 and B>127
Specificity	0.696
Sensitivity	0.701
AUC	0.748

and B > 127 for diagnosing *H. pylori*, the specificity, sensitivity, and AUC were 0.679, 0.681, and 0.712, respectively (Table 4).

Discussion

In many countries, *H. pylori* infection in the stomach has been routinely detected.^[10,11] The prevalence of *H. pylori* is on the increase, possibly with the increased awareness of the population on its importance. For patients with confirmed *H. pylori* infection, it is highly suggested that proper eradication therapy should be administrated, especially for those with high risk for gastric cancer.^[12,13] Gastrointestinal endoscopy can directly observe the changes of the gastric mucosa, which can help diagnose the presence of *H. pylori* infection in the stomach. However, white light endoscopy as the routine technique could not be able to differentiate such minor gastric mucosal lesions including *H. pylori* infected mucosa. Many new imaging and post-processing technique is being integrated into the field of endoscopic analysis.^[14-17] LCI endoscopic technique was specially designed to enhance the color contrast between normal and abnormal mucosa, making it easy for the endoscopists to identify.^[18] Thus, in this study, we objectively explored the clinical value of LCI application in diagnosing *H. pylori* in-

Table 1. Demographic and clinical characteristics of training set (n=166)

Training set (n=166)	Patients with <i>H. pylori</i> infection (n=25)	Patients without <i>H. pylori</i> infection (n=141)	p
Demographic and clinical characteristics			
Age, mean (range), years	46.7 (19–67)	45.3(18–63)	0.230
Male gender, n (%)	16 (64.0)	83 (58.7)	
Main symptoms, n (%)			
Heartburn	10 (40.0)	58 (41.1)	-
Stomach pain	9 (36.0)	53 (37.6)	-
Abdominal distension	6 (24.0)	30 (21.3)	-
Pathology for biopsy, n (%)			
Chronic atrophic gastritis	15 (60.0)	35 (24.8)	-
Chronic non-atrophic gastritis	10 (40.0)	106 (75.2)	-
Pixel brightness value calculations			
R	210.203±27.233	196.401±29.018	0.043
G	134.432±24.554	136.008±23.509	0.115
B	127.621±26.112	125.334±27.812	0.025

H. pylori: *Helicobacter pylori*.

Table 3. Demographic and clinical characteristics of the validation set (n=79)

Validation set	Patients with <i>H. pylori</i> infection (n=10)	Patients without <i>H. pylori</i> infection (n=69)	p
Demographic and clinical characteristics			
Age, mean (range), years	42.7 (18-68)	44.5(18-67)	0.380
Male gender, n (%)	7 (70.0)	45 (65.2)	
Main symptoms, n (%)			
Heartburn	5 (50.0)	33 (47.8)	-
Stomach pain	3 (30.0)	20 (29.0)	-
Abdominal distension	2 (20.0)	16 (23.2)	-
Pathology for biopsy, n (%)			
Chronic atrophic gastritis	16 (64.0)	20 (29.0)	-
Chronic non-atrophic gastritis	9 (36.0)	49 (71.0)	-
Pixel brightness value calculations			
R	212.311±28.004	197.106±28.182	0.031
G	137.633±24.470	135.012±24.926	0.102
B	128.718±28.202	124.984±27.832	0.044

H. pylori: *Helicobacter pylori*.

Table 4. Diagnostic efficacy analysis in the validation set

	R>210 and B>127
Specificity	0.679
Sensitivity	0.681
AUC	0.712

fection in the gastric antrum by introducing the RGB color mode and calculating pixel brightness values. These results could serve as a pilot artificial intelligence diagnostic system for screening *H. pylori* infection.

Conventionally, the endoscopic diagnosis has mainly depended on the judgment of the endoscopists and their experience. With the rapid development of the computerized science, the analysis of specific images can be introduced to the gastrointestinal endoscopy. Our previous study has already investigated the application of pixel brightness values in the objective analysis of color features of the endoscopic images for distal gastric diseases.^[9] Those results were consistent with other researches.^[19-21] Sun and Zhao also validated that RGB pixel brightness value can serve as a useful and objective parameter for distinguishing early gastric cancer from LCI images.^[19] Besides pixel brightness value, the International Commission on Illumination L*a*b* color space system can also be used to objectively assess the color differences of the images,^[22,23] but the later is more complicated and difficult to understand than the former. All these quantifiable parameters will be of vital importance in the establishment of artificial intelligence model for gastrointestinal endoscopy.^[24]

A training set and a validation set were both enrolled in this study. We first optimized the cut-off value of pixel brightness value for differentiating *H. pylori* infection from normal mucosa based on the data from training set and then validated the cut-off value in the validation set. The demographical and clinical characteristics between patients with and without *H. pylori* infection in both two sets were comparable (all $p < 0.05$). Our results demonstrated that the criteria of $R > 210$ and $B > 127$ used for diagnosing *H. pylori* were relatively specific and sensitive (training set 0.696 and 0.701 vs. validation set 0.679 and 0.681), which can be recommended in clinical application.

There were still limitations in our study. First, all the patients were from one single center, and the sample size was small. A multi-center large-scale investigation could be planned for both internal and external validation. Second, we did not include patients with previous history of *H. pylori* infection or eradication, and all the patients underwent esophagogastroduodenoscopy for the 1st time. The diagnostic role of pixel brightness value for patients with *H. pylori* eradication could be further examined in our future research.

Disclosures

Ethics Committee Approval: This protocol was reviewed and approved by the Ethic Committee of the Fifth Medical Center of Chinese PLA General Hospital (the 307 Hospital of Academy of Military Medical Science) in accordance with the Declaration of Helsinki, approval number March 20, 2017. All the patients gave their written informed consent.

Data Availability Statement: All data generated or analyzed during this study are included in this article. Further, inquires can be directed to the corresponding author.

Funding: This work was supported by Beijing Municipal Natural Science Foundation (N0.7214251, to Xiaotian Sun).

Peer-review: Externally peer-reviewed.

Conflict of Interest: None declared.

Authorship Contributions: Concept – X.S., C.M., X.M.; Design – X.S., Y.X.; Supervision – M.L., H.Z.; Materials – W.Z., Y.W., S.Z.; Data collection &/or processing – X.Z., C.L., H.Y.; Analysis and/or interpretation – X.S., C.M.; Literature search – X.Z., C.L.; Writing – X.S., C.M.; Critical review – X.S., X.M., Y.X.

References

- Li H, Hou X, Lin R, Fan M, Pang S, Jiang L, et al. Advanced endoscopic methods in gastrointestinal diseases: a systematic review. *Quant Imaging Med Surg* 2019;9:905–20.
- East JE, Vleugels JL, Roelandt P, Bhandari P, Bisschops R, Dekker E, et al. Advanced endoscopic imaging: European Society of Gastrointestinal Endoscopy (ESGE) Technology Review. *Endoscopy* 2016;48:1029–45.
- Li L, Tan J, Liu L, Li J, Chen G, Chen M, et al. Association between H. pylori infection and health Outcomes: an umbrella review of systematic reviews and meta-analyses. *BMJ Open* 2020;10:e031951.
- Feng-Woei T, Ping-I HH. pylori infection and extra-gastrointestinal diseases. *J Biomed Sci* 2018;25:65.
- Abo-Amer YE, Sabal A, Ahmed R, Hasan NFE, Refaie R, Mostafa SM, et al. Relationship between helicobacter pylori infection and nonalcoholic fatty liver disease (NAFLD) in a developing country: a cross-sectional study. *Diabetes Metab Syndr Obes* 2020;13:619–25.
- Howden CW, Graham DY. Recent developments pertaining to H. pylori infection. *Am J Gastroenterol* 2021;116:1–3.
- Sun X, Bi Y, Dong T, Min M, Shen W, Xu Y, et al. Linked colour imaging benefits the endoscopic diagnosis of distal gastric diseases. *Sci Rep* 2017;7:5638.
- Sun X, Bi Y, Nong B, Hu DM, Sun XM, Chen HL, et al. Linked color imaging confers benefits in profiling H. pylori infection in the stomach. *Endosc Int Open* 2019;7:E885–92.
- Sun X, Dong T, Bi Y, Min M, Shen W, Xu Y, et al. Linked color imaging application for improving the endoscopic diagnosis accuracy: a pilot study. *Sci Rep* 2016;6:33473.
- Bordin DS, Voynovan IN, Andreev DN, Maev IV. Current helicobacter pylori diagnostics. *Diagnostics (Basel)* 2021;11:1458.
- Alboraei M, Elhossary W, Aly OA, Abbas B, Abdelsalam L, Ghaith D, et al; special interest group; Egyptian Association for Study of Gastrointestinal Diseases and Liver (E A S G L D). Egyptian recommendations for management of Helicobacter pylori infection: 2018 report. *Arab J Gastroenterol* 2019;20:175–9.
- Abd-Elsalam S, Kobtan A, El-Kalla F, Elkhawany W, Nawasany SE, Saif SA, et al. A 2-week Nitazoxanide-based quadruple treatment as a rescue therapy for Helicobacter pylori eradication: A single center experience. *Medicine (Baltimore)* 2016;95:e3879.
- Shehata MA, Talaat R, Soliman S, Elmesseri H, Soliman S, Abd-Elsalam S. Randomized controlled study of a novel triple nitazoxanide (NTZ)-containing therapeutic regimen versus the traditional regimen for eradication of Helicobacter pylori infection. *Helicobacter* 2017;22:e12395.
- Hiraoka Y, Miura Y, Osawa H, Nomoto Y, Takahashi H, Tsunoda M, et al. Appropriate color enhancement settings for blue laser imaging facilitates the diagnosis of early gastric cancer with high color contrast. *J Gastric Cancer* 2021;21:142–54.
- Ono S, Shimoda Y, Tanaka I, Kinowaki S, Inoue M, Ono M, et al. Optical effect of spraying l-menthol on gastric intestinal metaplasia visualized by linked color imaging. *Eur J Gastroenterol Hepatol* 2021;33:358–63.
- Sakae H, Kanzaki H, Satomi T, Okanoue S, Obayashi Y, Hamada K, et al. Linked color imaging (LCI) emphasizes the color changes in the gastric mucosa after helicobacter pylori eradication. *Dig Dis Sci* 2022;67:2375–84.
- Lee SP, Lee J, Kae SH, Jang HJ, Koh DH, Jung JH, et al. The role of linked color imaging in endoscopic diagnosis of Helicobacter pylori associated gastritis. *Scand J Gastroenterol* 2020;55:1114–20.
- Ono S, Kawada K, Dohi O, Kitamura S, Koike T, Hori S, et al; LCI-FIND Trial Group. Linked color imaging focused on neoplasm detection in the upper gastrointestinal tract : a randomized trial. *Ann Intern Med* 2021;174:18–24.
- Sun X, Zhao L. RGB pixel brightness characteristics of linked color imaging in early gastric cancer: a pilot study. *Gastroenterol Res Pract* 2020;2020:2105874.
- Ishikawa T, Matsumura T, Okimoto K, Nagashima A, Shiratori W, Kaneko T, et al. Efficacy of texture and color enhancement imaging in visualizing gastric mucosal atrophy and gastric neoplasms. *Sci Rep* 2021;11:6910.
- Fujiyoshi T, Miyahara R, Funasaka K, Furukawa K, Sawada T, Maeda K, et al. Utility of linked color imaging for endoscopic diagnosis of early gastric cancer. *World J Gastroenterol* 2019;25:1248–58.
- Jiang ZX, Nong B, Liang LX, Yan YD, Zhang G. Differential diagnosis of Helicobacter pylori-associated gastritis with the linked-color imaging score. *Dig Liver Dis* 2019;51:1665–70.
- Wang L, Lin XC, Li HL, Yang XS, Zhang L, Li X, et al. Clinical significance and influencing factors of linked color imaging technique in real-time diagnosis of active Helicobacter pylori infection. *Chin Med J (Engl)* 2019;132:2395–401.
- Abadir AP, Ali MF, Karnes W, Samarasena JB. Artificial Intelligence in Gastrointestinal Endoscopy. *Clin Endosc* 2020;53:132–41.